

# Assisted Capsule Endoscopy

AdvanCE™ Case Report Series • Report 3



**“Very simple to endoscopically place the capsule under conscious sedation into the stomach or duodenum.”**

Robert A. Muggia, M.D.  
Chief of GI  
Winchester Hospital  
Winchester, MA

## Procedure

- EGD with video capsule placement

## Indications for Capsule Endoscopy

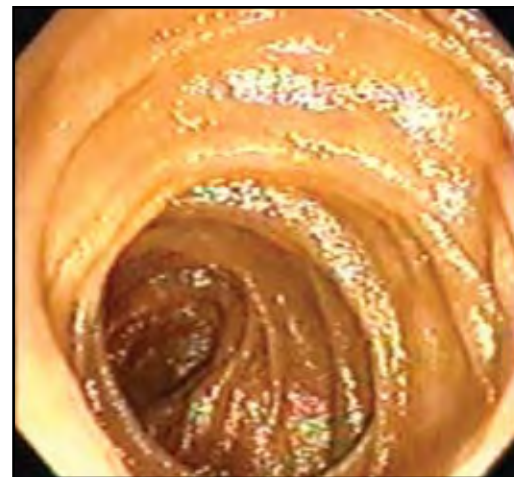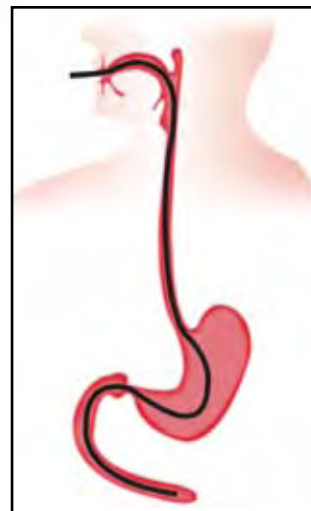- Idiopathic Iron Deficiency Anemia

## Indications for AdvanCE™ Device


- Phobic aversion to pill swallowing

## Assisted Capsule Endoscopy

After adequate conscious sedation was achieved, the scope was advanced under direct visualization to the 3rd portion of the duodenum for baseline evaluation. No source of anemia determined; video capsule placement elected. The scope was withdrawn and the AdvanCE™ device loaded for endoscopic video capsule delivery. Deployment of the video capsule into the 2nd portion of the duodenum was successful.



1. Direct visualization of the duodenum



2. AdvanCE device's empty capsule cup after successful video capsule deployment



listening...and delivering solutions

5976 Heisley Road  
Mentor OH 44060

phone 440 / 639,4494

fax 440 / 639,4495

customer service 800 / 769,8226

[www.usendoscopy.com](http://www.usendoscopy.com)

This case report is not intended to provide device or clinical instruction or intended to be a substitute for the Instructions For Use (IFU) which are packaged with the device. Please consult the IFU prior to using the AdvanCE™ capsule endoscope delivery device. AdvanCE™ is a trademark of US Endoscopy, patent pending.